

«ΚΟΛΠΙΚΗ ΜΑΡΜΑΡΥΓΗ» – ΚΛΙΝΙΚΑ ΠΡΟΒΛΗΜΑΤΑ ΙΙ

**ΠΟΙΑ ΤΕΧΝΙΚΗ ΚΑΤΑΛΥΣΗΣ ΧΡΗΣΙΜΟΠΟΙΩ.
ΔΥΝΑΤΟΤΗΤΕΣ ΚΑΙ ΠΡΑΚΤΙΚΑ ΠΡΟΒΛΗΜΑΤΑ.
CARTO 3.**

Μιχάλης Εφραιμίδης MD

Εργαστήριο Ηλεκτροφυσιολογίας

Β' Καρδιολογική Κλινική

Νοσοκομείο ' ' Ο ΕΥΑΓΓΕΛΙΣΜΟΣ ' '



ΠΟΙΑ ΤΕΧΝΙΚΗ ΚΑΤΑΛΥΣΗΣ ΧΡΗΣΙΜΟΠΟΙΩ

Τεχνική Προσέγγισης στην κατάλυση κοιλιακής μαρμαρυγής

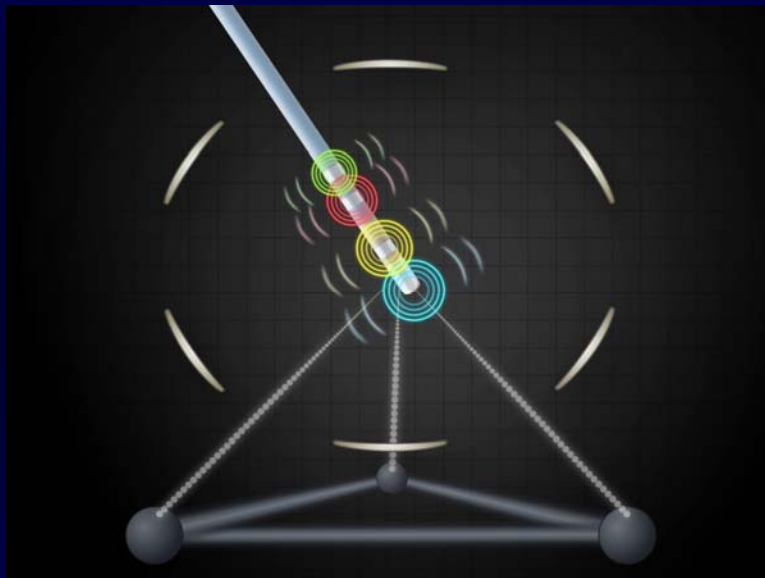
- Ηλεκτρική απομόνωση PV's
- + γραμμική κατάλυση σε εμμένουσα κοιλιακή μαρμαρυγή
- Επιβεβαίωση με αποκλεισμό εισόδου & εξόδου πνευμονικών φλεβών

Εξέλιξη του συστήματος CARTO

- 1999 – CARTO Unix
- 2002 – CARTO XP
- 2009 – CARTO 3

Advanced Catheter Location (ACL)


Ακρίβεια
Electromagnetic mapping



In vivo accuracy <1mm

+

Απεικόνιση
Current based mapping



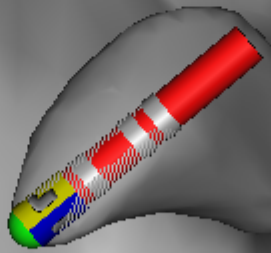
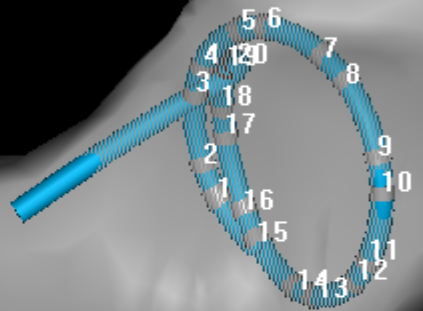
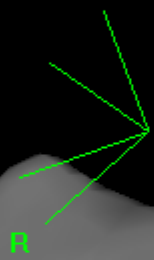
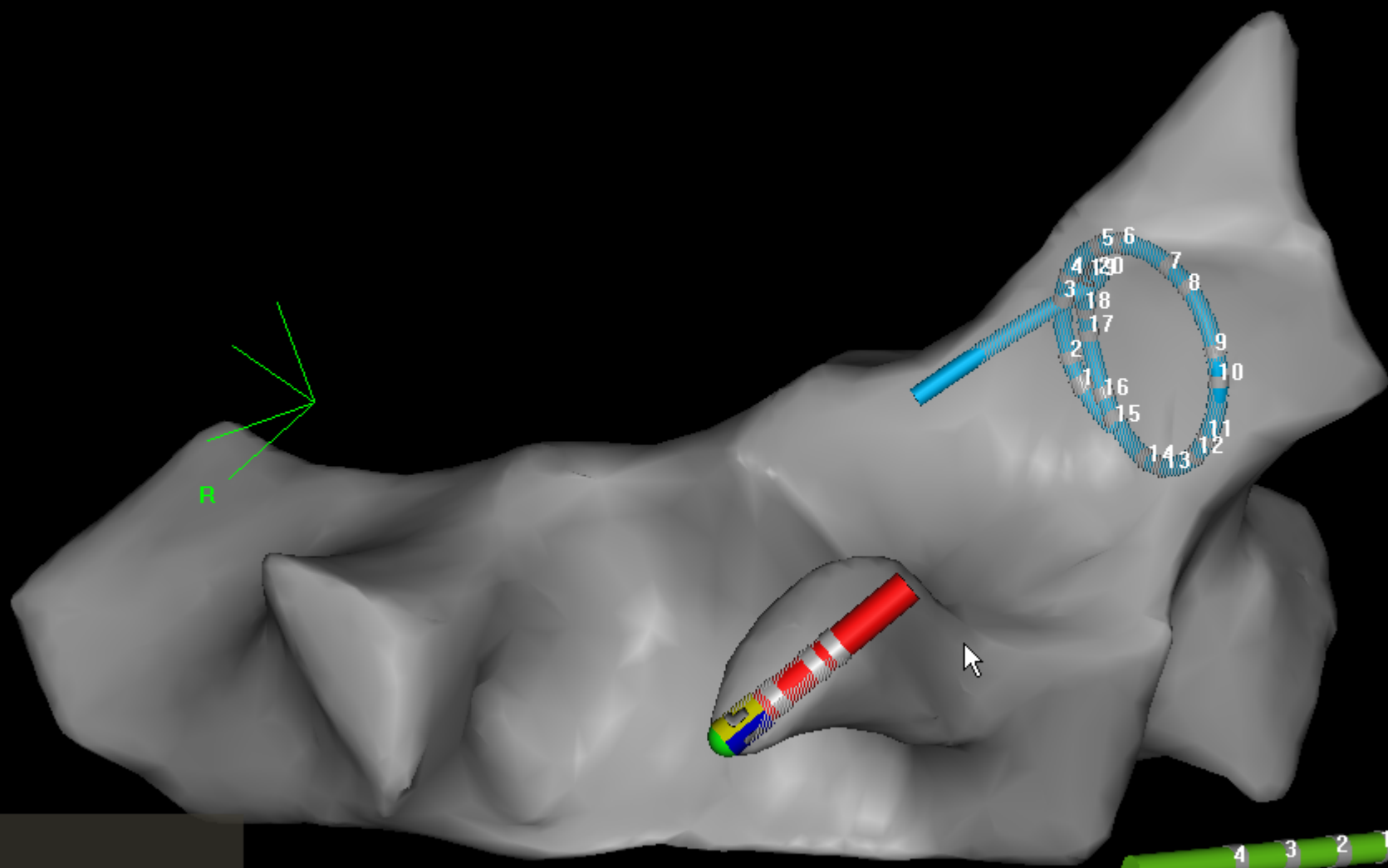

Catheter visualization



1^{ος} Ασθενής

- Άνδρας - 64 χρόνων
- Ιστορικό 7 χρόνων παροξυσμικής κολπικής μαρμαρυγής ανθεκτικής στην προπαφαινόνη & καρβεδιλόλη.
- Ιστορικό υπέρτασης.
- Φυσιολογικό κλάσμα εξώθησης & μέγεθος αριστερού κόλπου.

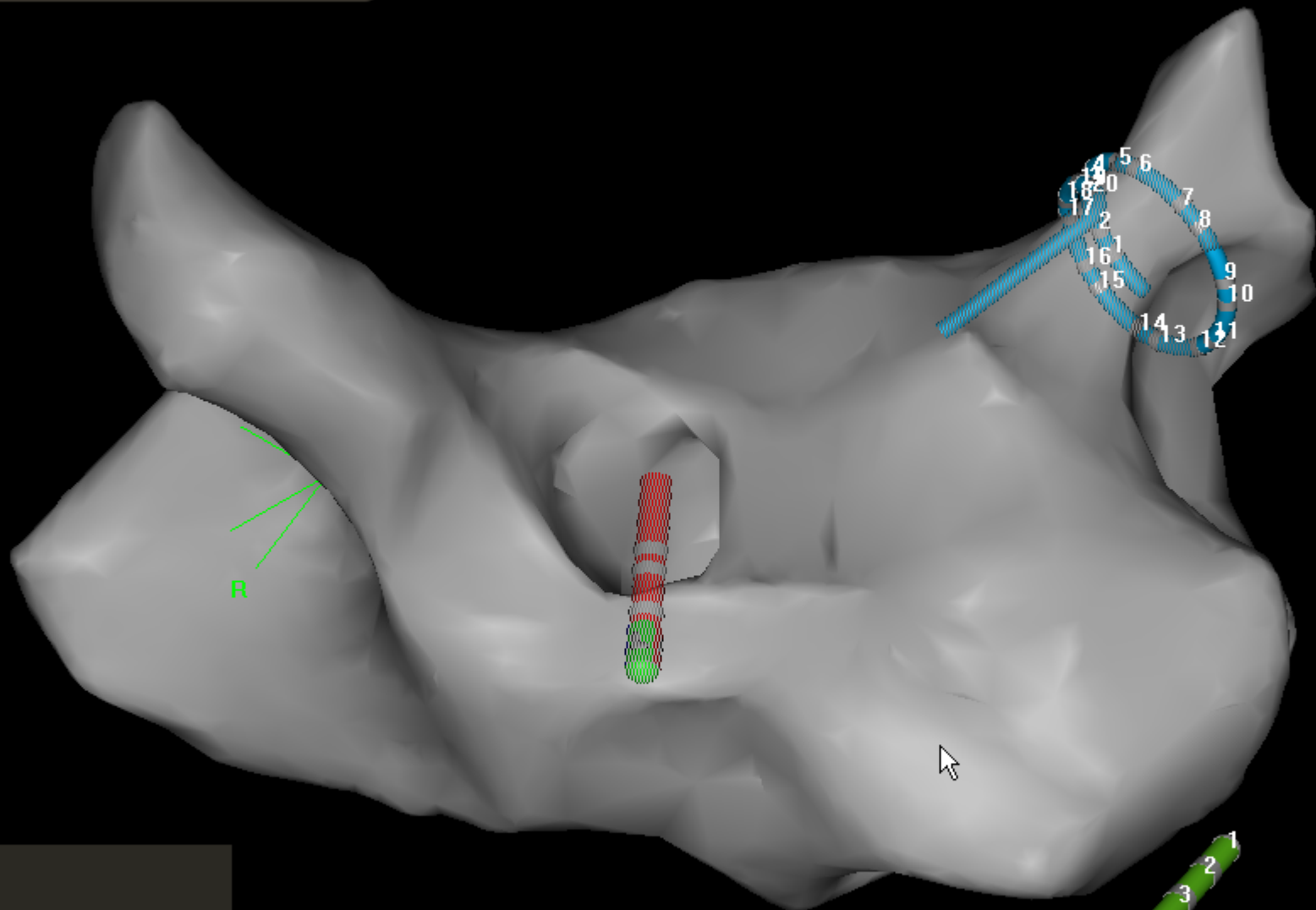
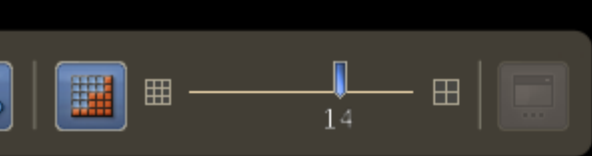
Fast Anatomical Mapping



LAT Bi Imp
 60 0.46 N/A

Volume: 51.58 RAO:
 Caudal: 18° Swivel:

AP PA LAO



R

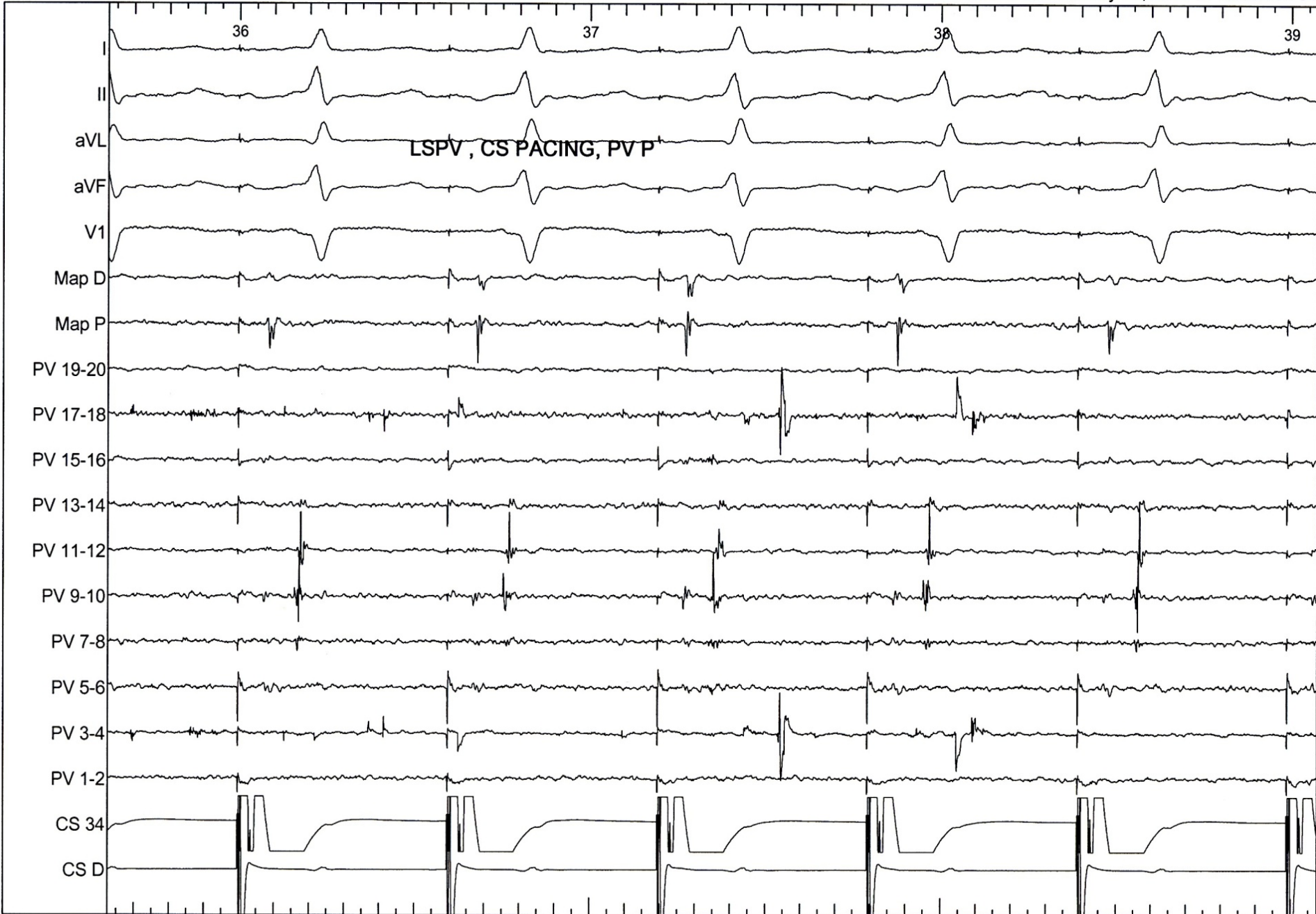


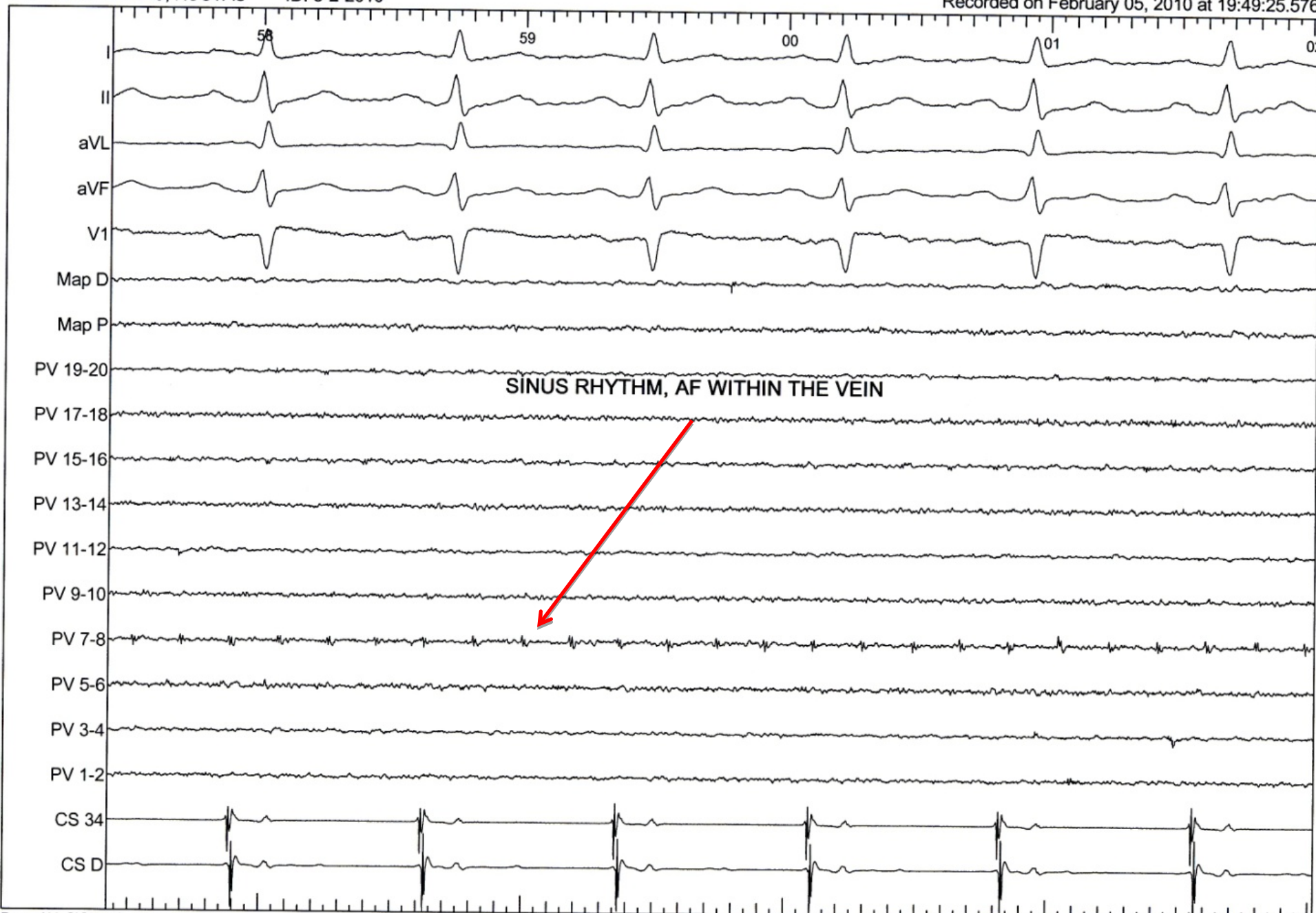Volume: 121.31 RAO:
Cranial: 2 ° Swivel:

LAT	Bi	Imp
-91	0.12	N/A

AP PA LAO

Segmental ablation



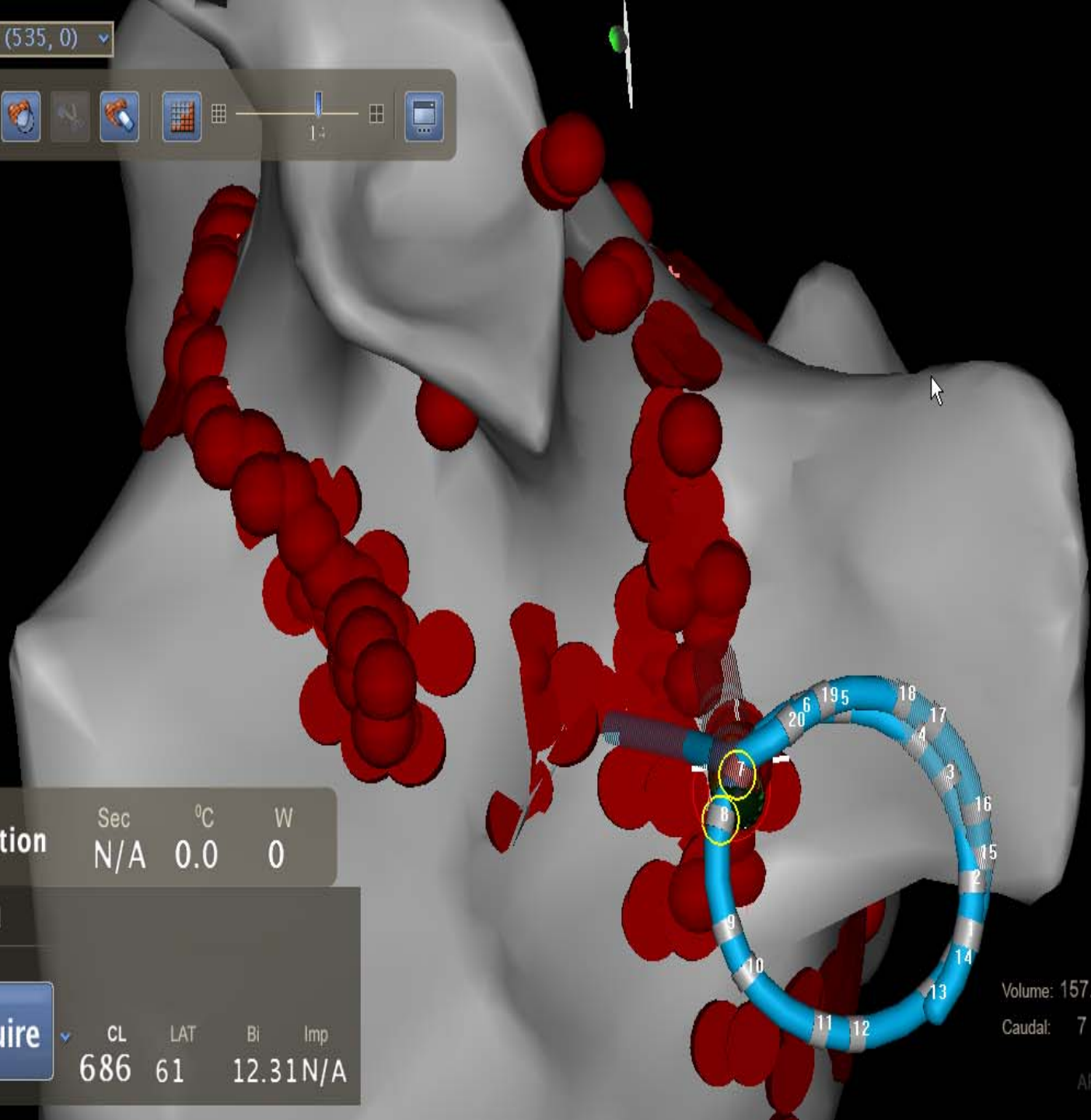


4-Map (535, 0)



LAT

Navigation and tool icons including a globe, a hand, a pencil, a blue tool, a grid, a zoom slider, and a monitor icon.

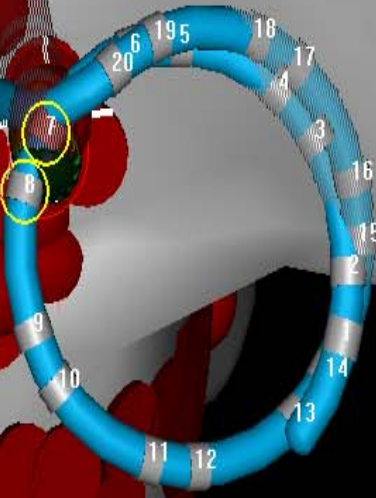


Ablation	Sec	°C	W
	N/A	0.0	0

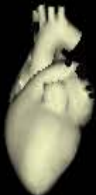Manual

Acquire

CL	LAT	Bi	Imp
686	61	12.31	N/A



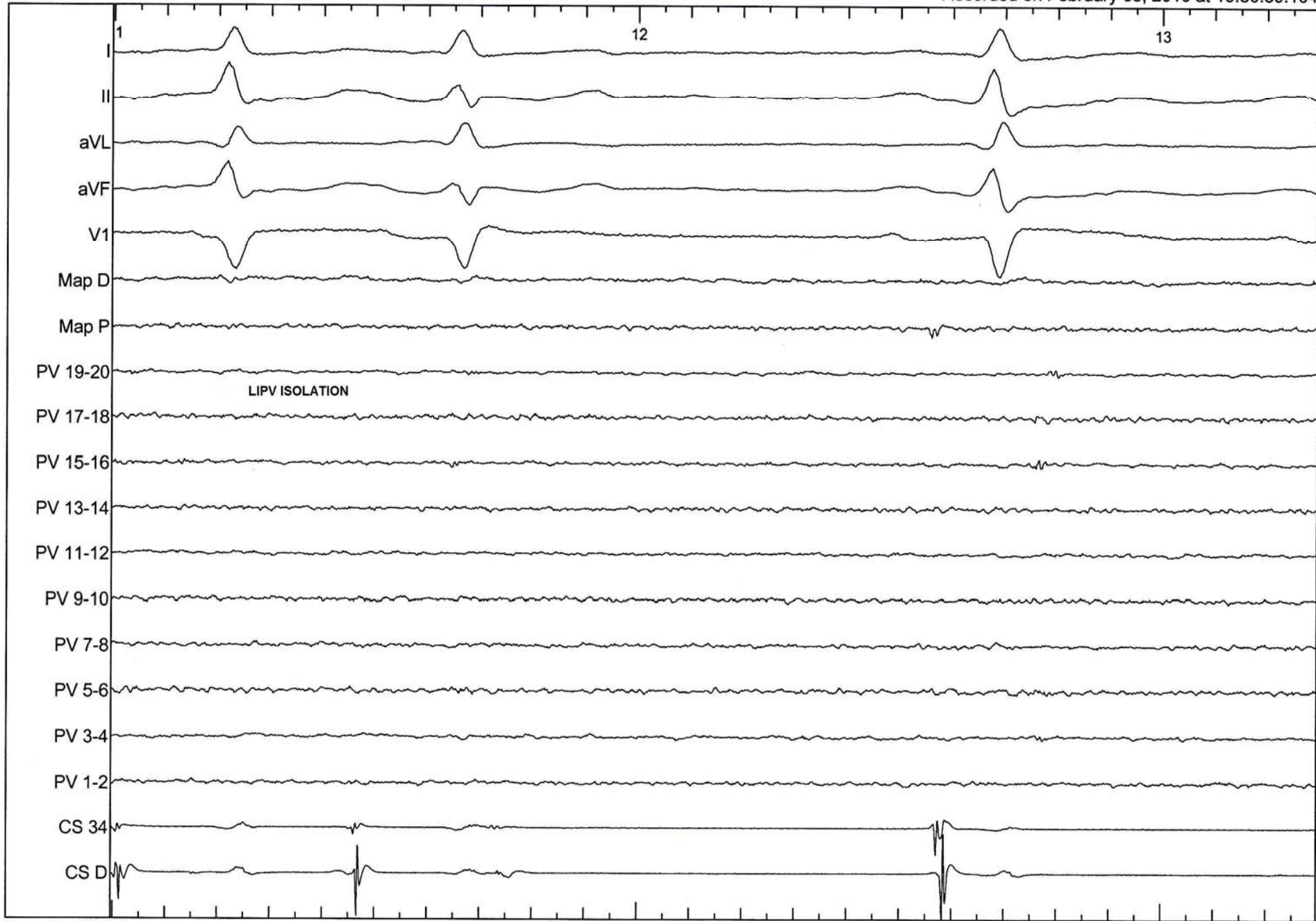
Volume: 157.41 RAO: 128°
 Caudal: 7° Swivel: 145°

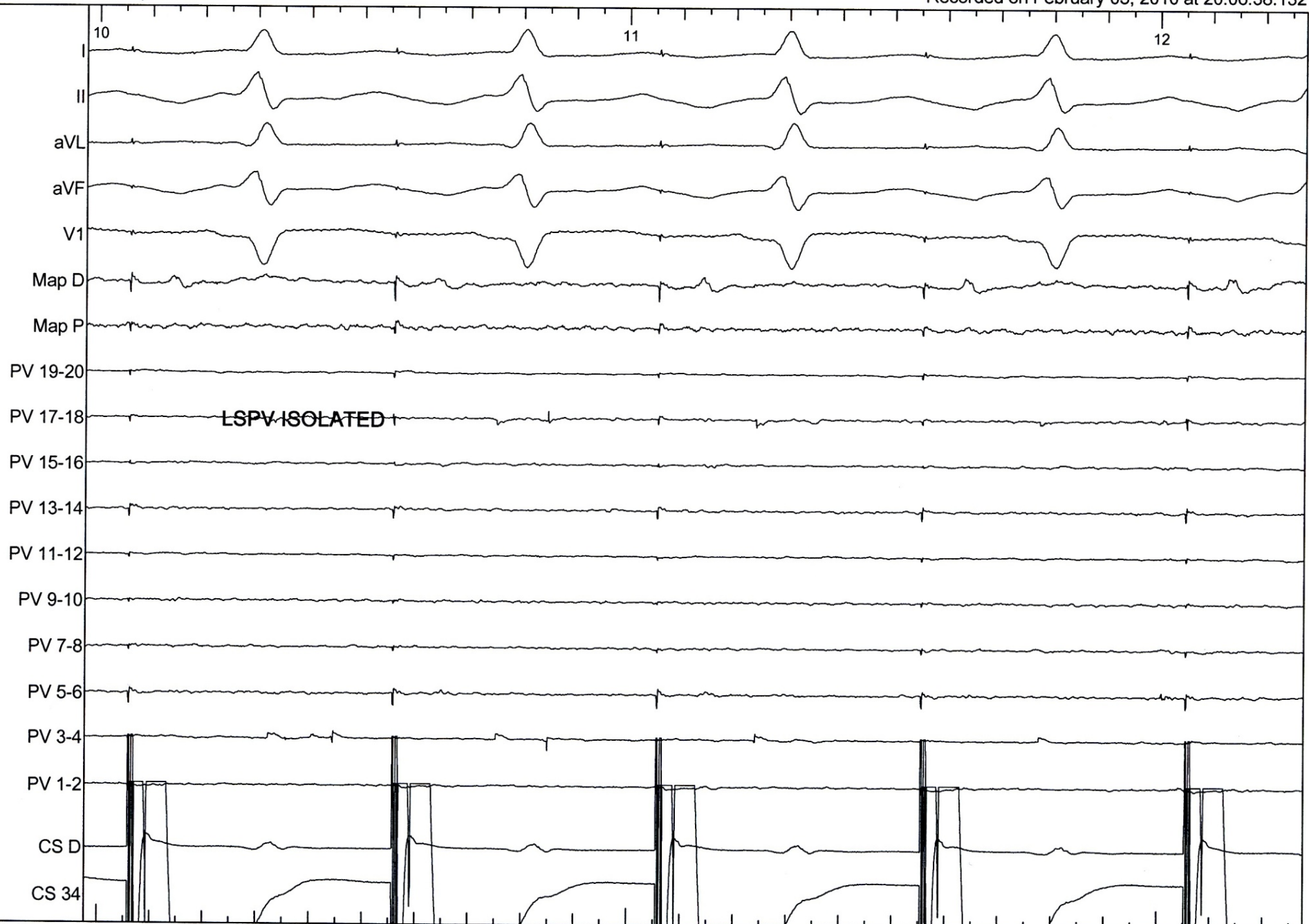


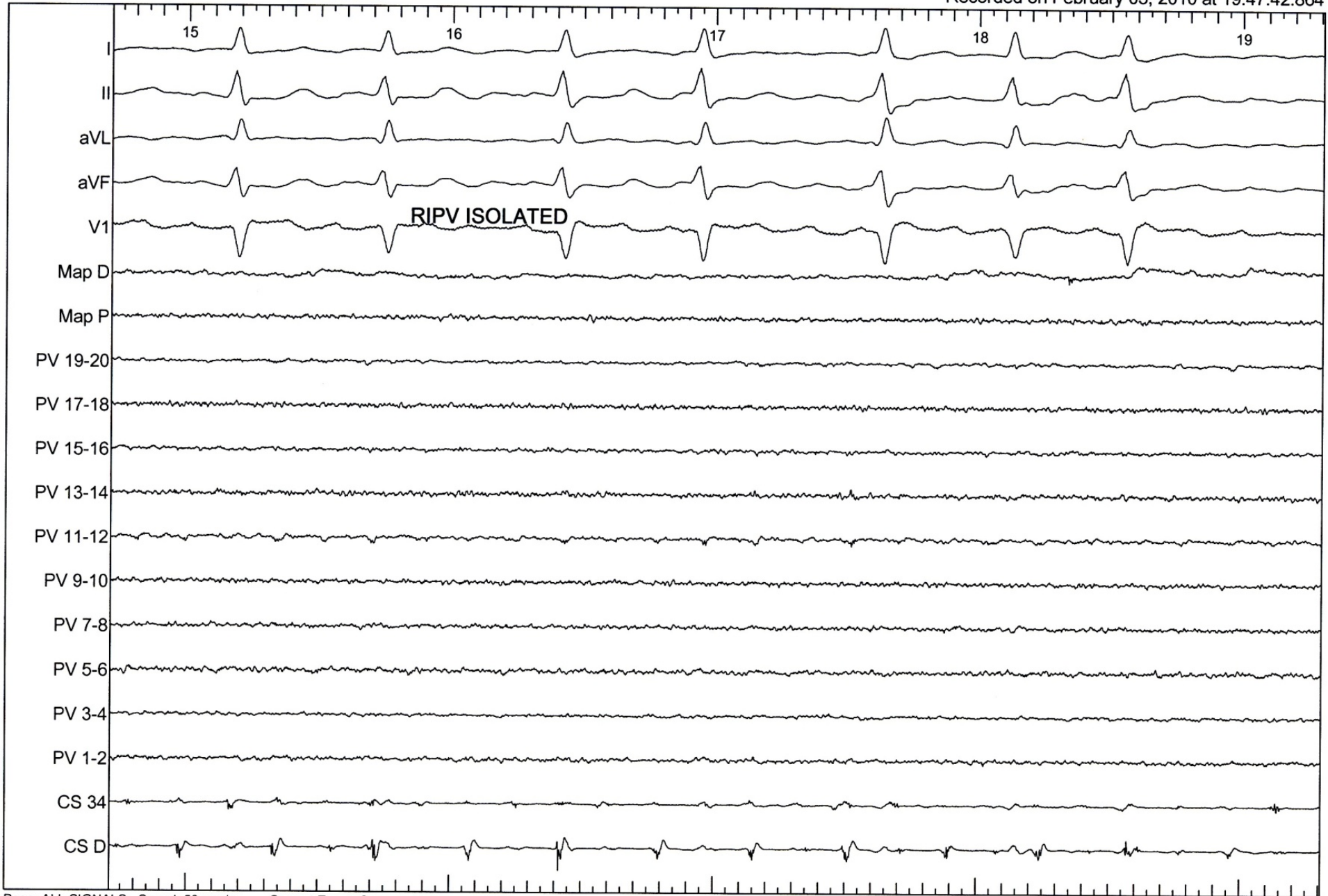
0.51

Navigation controls including a vertical slider, a heart icon, and a globe icon.

AP PA LAO RAO LL RL INF SUP







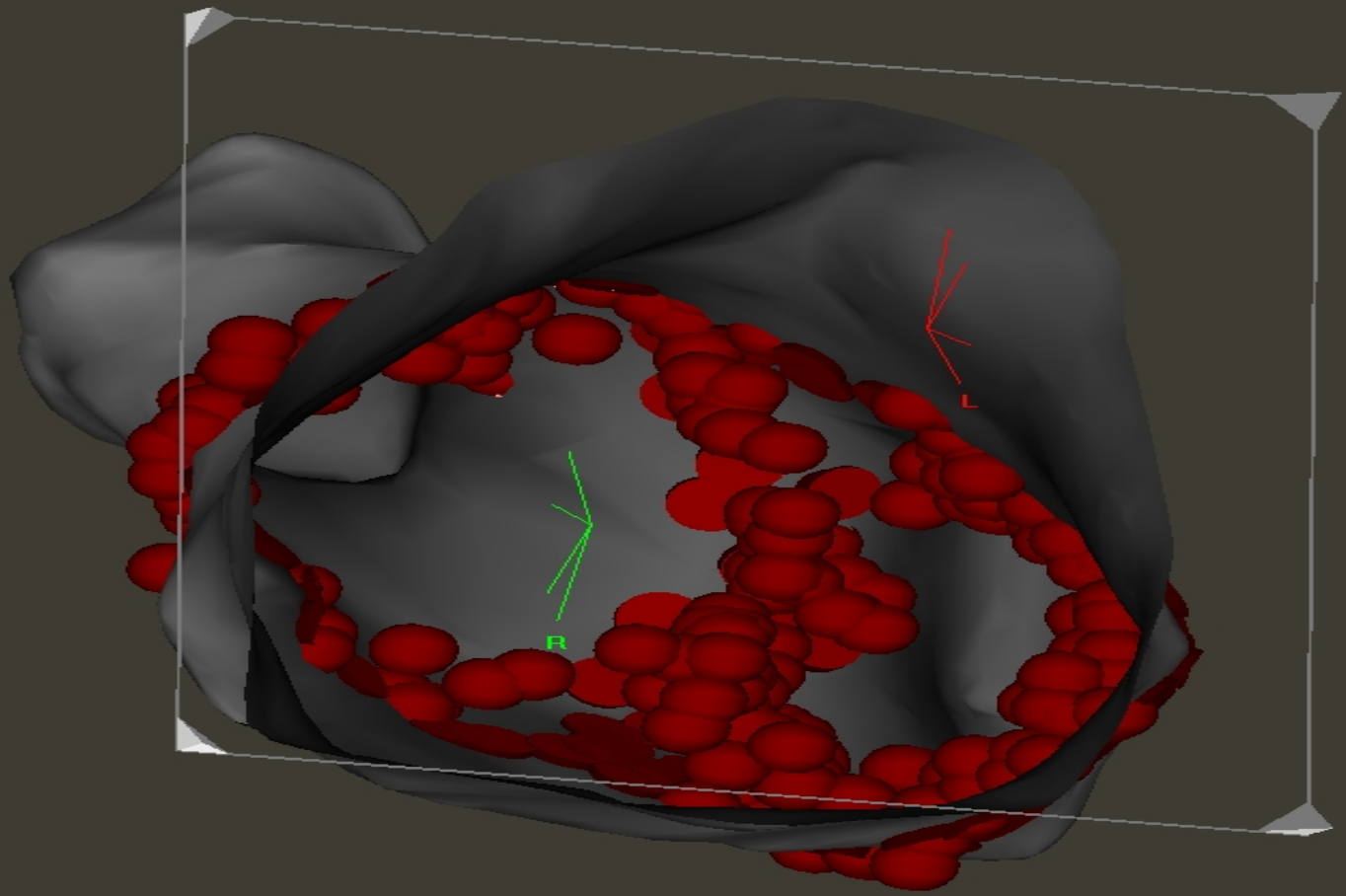
4-Map (512, 0)

- 1-Map (map)
- 2-Map (map)
- 3-Map (fam)
- 4-Map (fam)

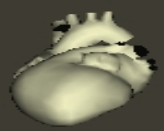


LAT

Navigation and zoom controls including a mouse icon, a grid icon, a zoom slider set to 1.4, and a monitor icon.



0.83



Vertical navigation controls including a plus sign, a slider, a minus sign, and two heart icons.

AP PA LAO RAO LL RL INF SUP




2^{ος} Ασθενής

- Άνδρας 60 χρόνων.
- Εμμένουσα κοιλιακή μαρμαρυγή τα τελευταία 10 έτη.
- Τους τελευταίους 6 μήνες σε κοιλιακή μαρμαρυγή.
- Διάμετρος αριστερού κόλπου 55 mm.

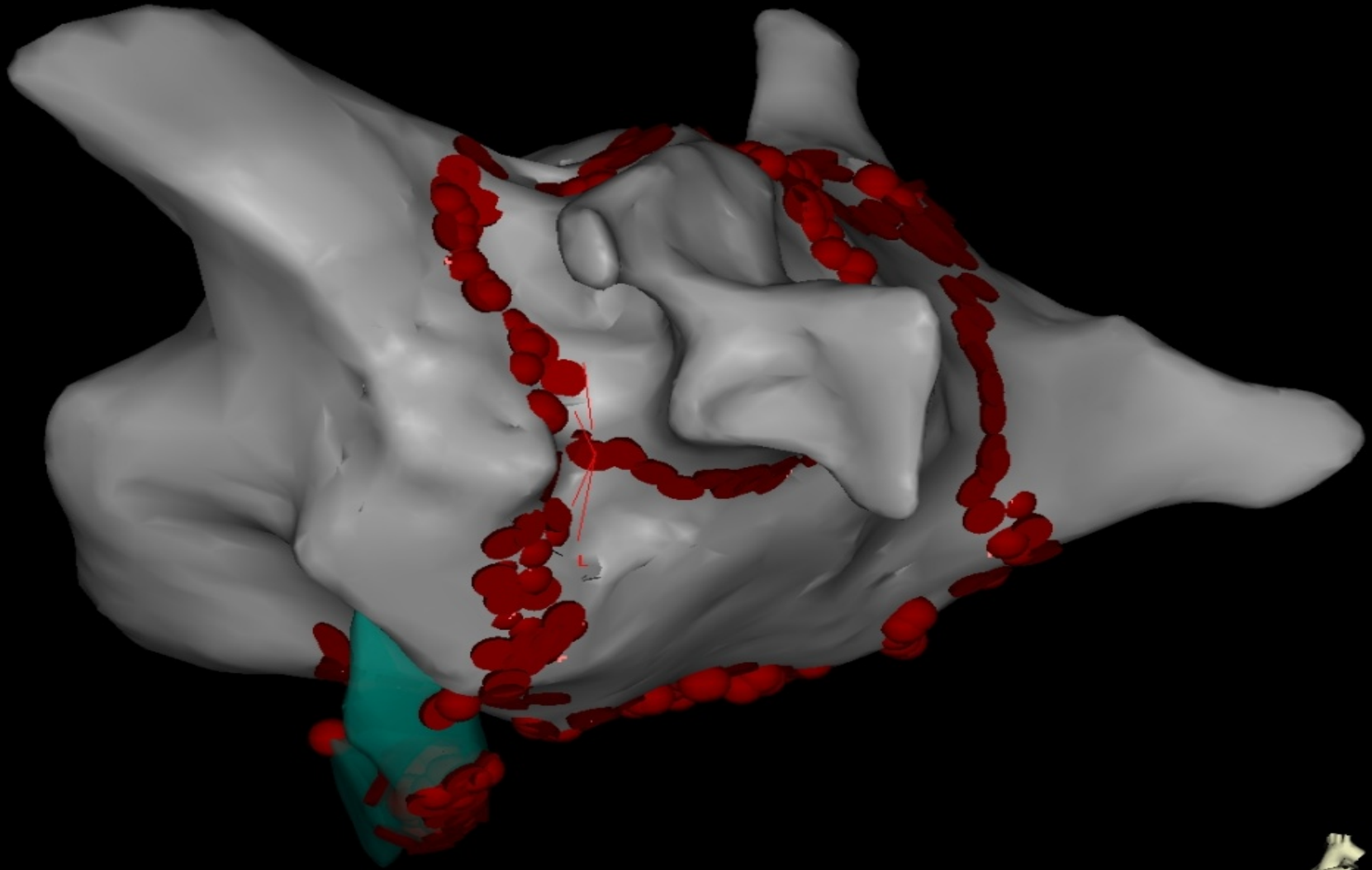
**Less
Fluoroscopy**

3-Map (485, 0)



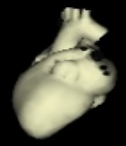LAT

Navigation toolbar containing icons for: Home, 3D Map, 2D Map, 3D Model, Grid, Scale (14), and Monitor.

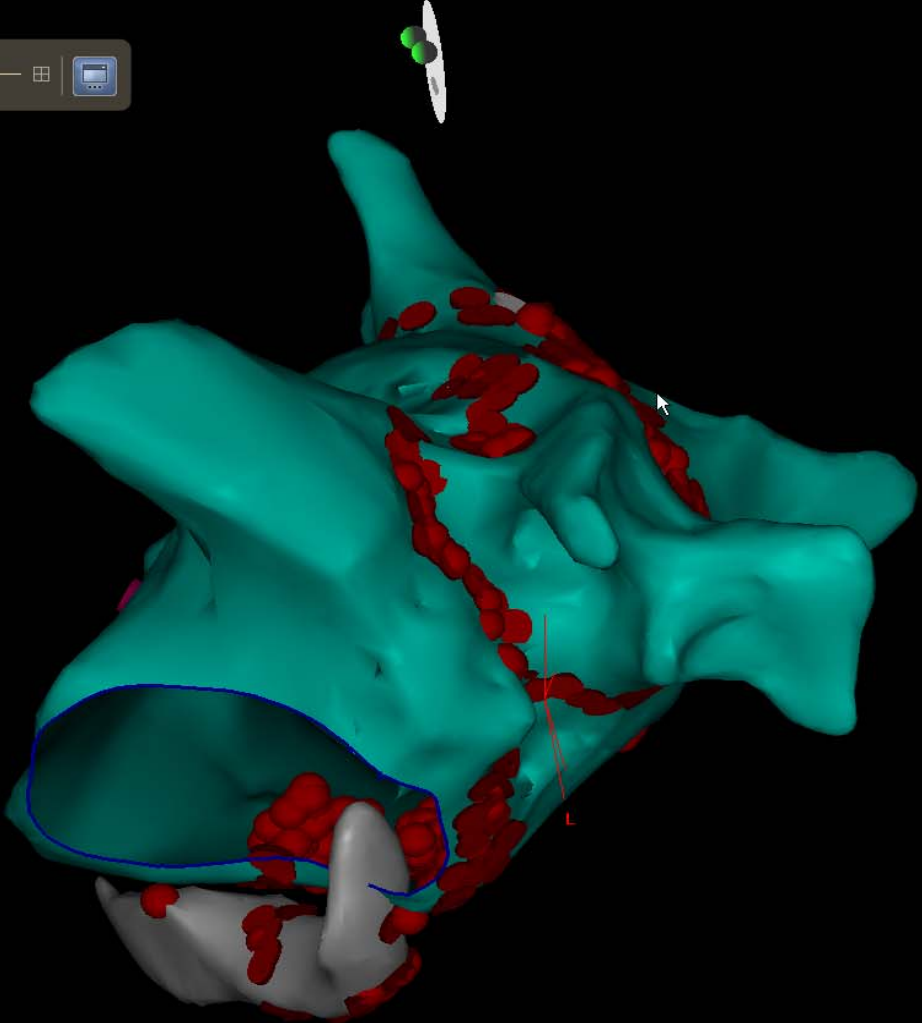


1.21

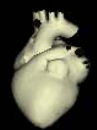Vertical navigation controls including a zoom slider and directional buttons (up, down, left, right).



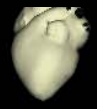AP PA LAO RAO LL RL INF SUP



1.33



AP PA LAO RAO LL RL INF SUP

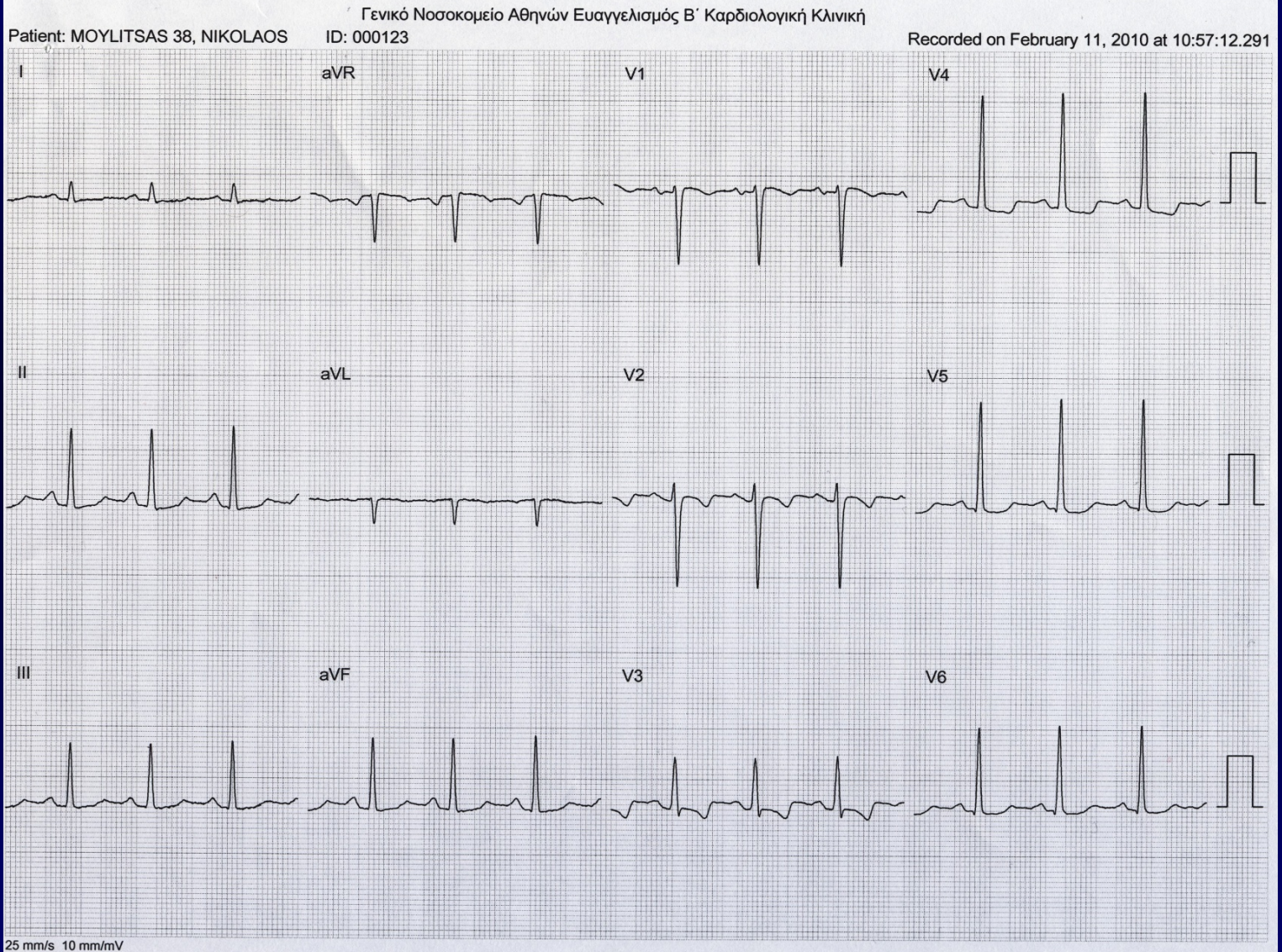


AP PA LAO RAO LL RL INF SUP

Precision in Fast Voltage mapping



Right Ventricular Dysplasia





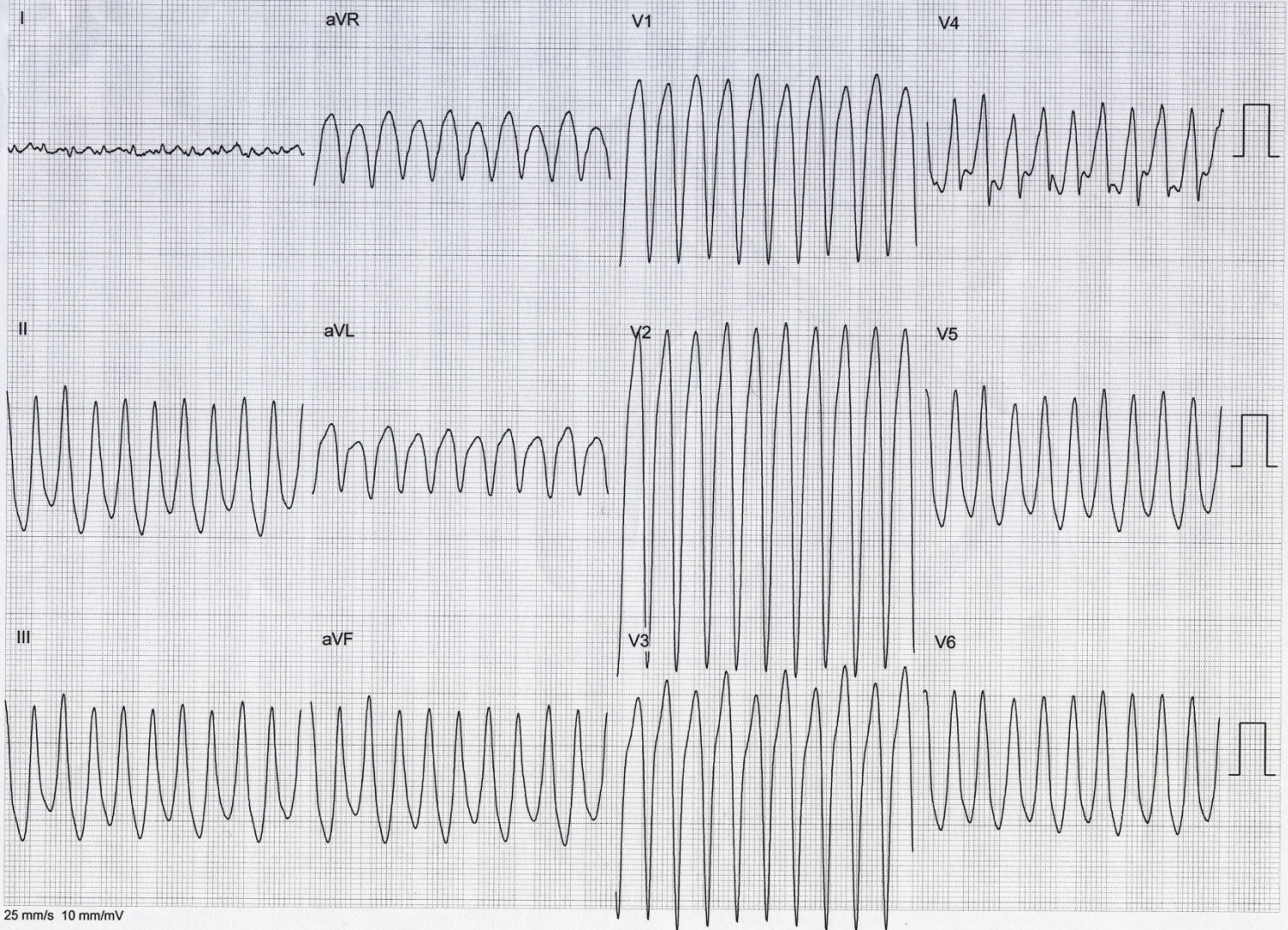
Right Ventricular Dysplasia

Patient: MOYLITSAS 38, NIKOLAOS

ID: 000123

Γενικό Νοσοκομείο Αθηνών Ευαγγελισμός Β' Καρδιολογική Κλινική

Recorded on February 11, 2010 at 11:18:32.411

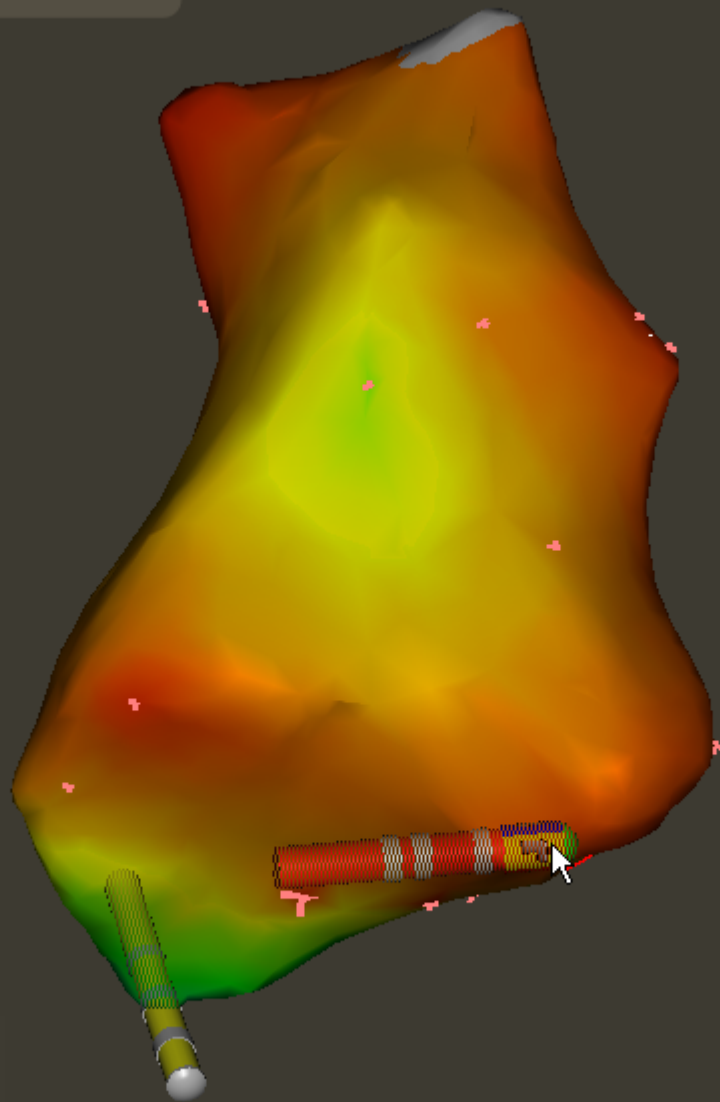




, 0)

0.07 mV



Navigation toolbar with icons for: a hand, a pencil, a grid, a zoom slider (set to 14), a window icon, and a settings icon.



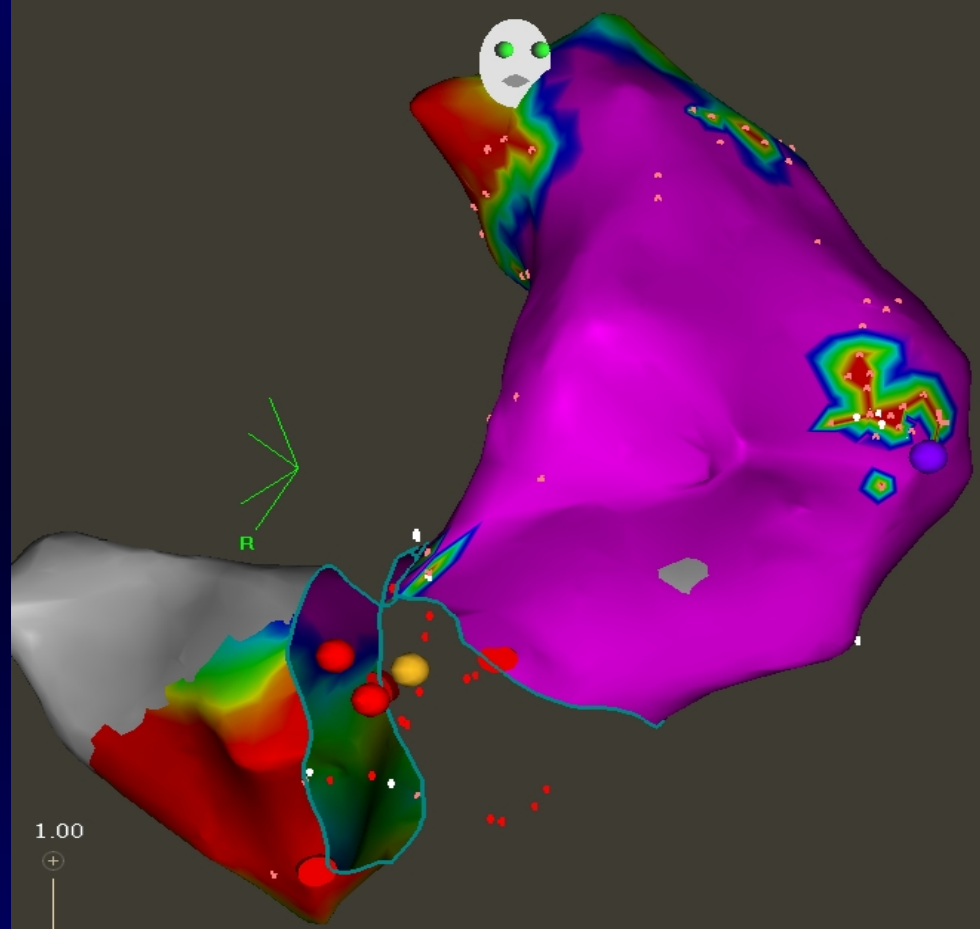
CL	LAT	Bi	Imp
808	17	0.18	N/A

2-Map (140, 0) ▾

0.07 mV 131.07 mV

0.521.71

Bipolar



1.00

+

○

-

♥

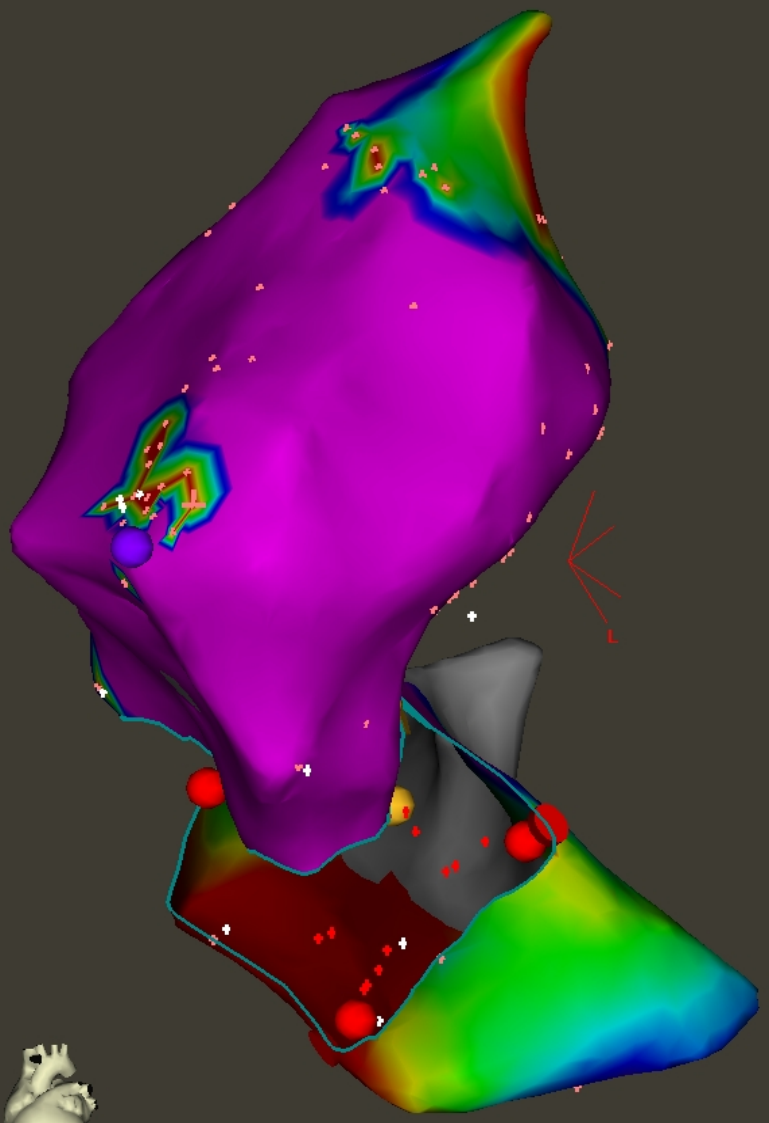
♥

AP PA LAO RAO LL RL INF SUP

None ▾

2-Map (140, 0) ▾

0.07 mV 131.07 mV
0.521.71
Bipolar



0.83

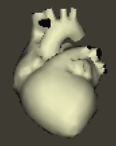+

○

-

⊖

⊖



AP PA LAO RAO LL RL INF SUP

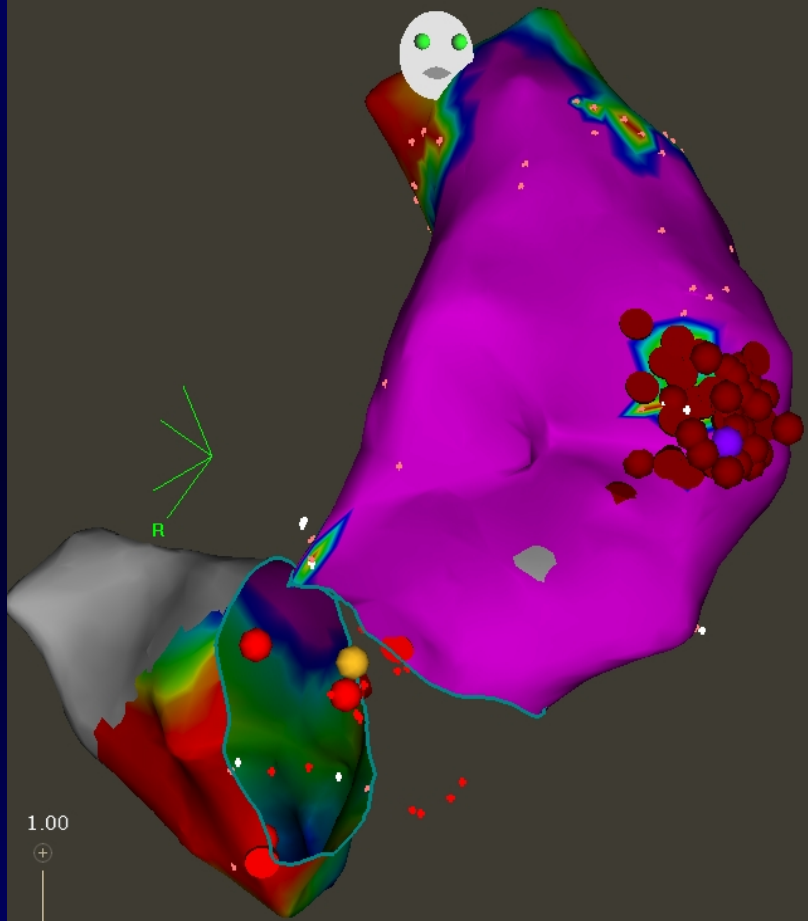
None ▾

2-Map (227, 0)

0.07 mV 131.07 mV

0.521.71

Bipolar



1.00

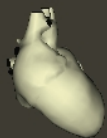+

●

-

⊖

⊖



AP PA LAO RAO LL RL INF SUP

None

2-1-... (231, 0)

-100.00 ms

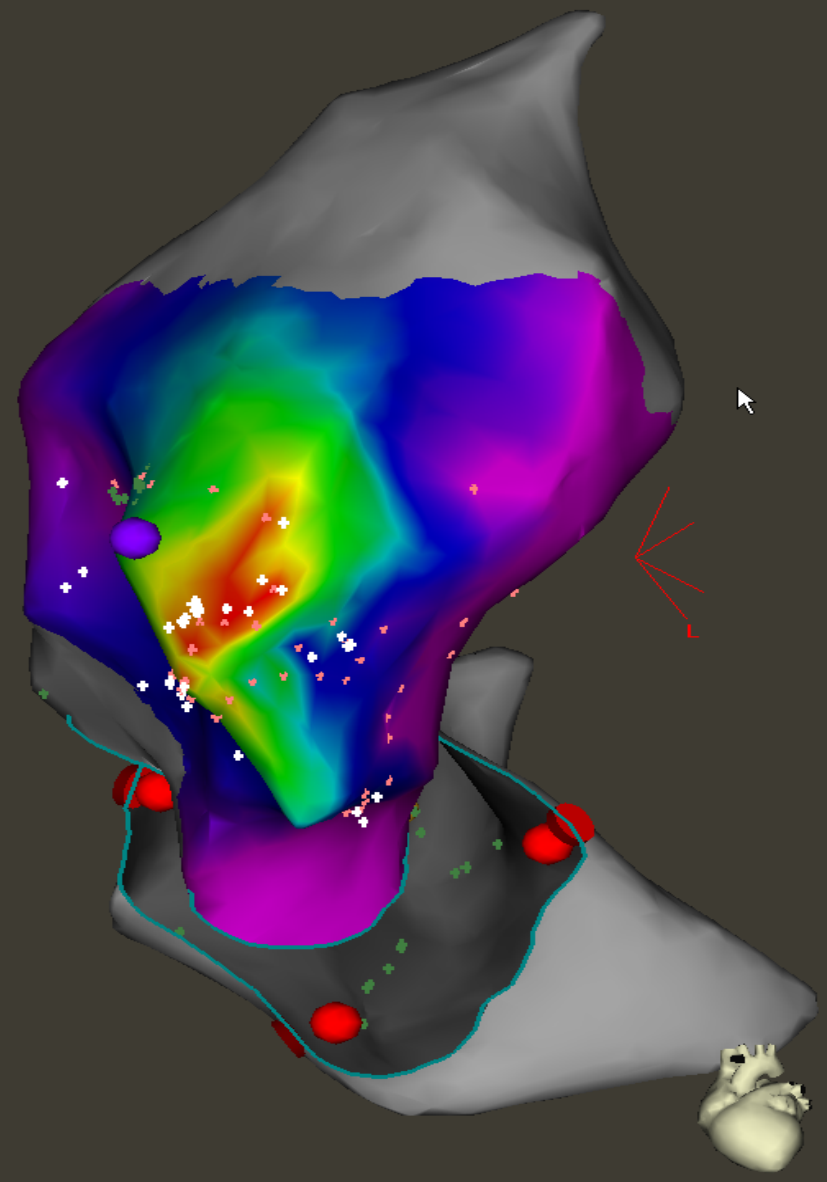


-26.00 ms

-87.40

-39.88
LAT

Navigation toolbar with icons for: Home, Rotate, Zoom, Pan, Grid, Scale (1.4), and a small monitor icon.



0.83

Vertical zoom control with a slider and '+' and '-' buttons.

AP PA LAO RAO LL RL INF SUP



Α. Σιδέρης
Δ. Μανωλάτος
Κ. Λέτσας
Σ. Ξυδώννα
Π. Σκουφογιάννη

